

Comparison of Conventional 2.0 mm Non-Locking and Locking Miniplates in Management of Fracture Mandible

Madhulika Yadav¹, Nirma Yadav², Anand Kumar²

¹Department of Dental Surgery, Government Medical College, Kannauj, Uttar Pradesh, India, ²Department of Dental Surgery, Moti Lal Nehru Medical College, Allahabad, Uttar Pradesh, India

ABSTRACT

Aim: This study aims to compare post-operative evaluation of locking and non-locking miniplates in mandibular fractures. **Materials and Methods:** The study consisted sample size of 40 patients non-comminuted fractures (40 fracture sites) were divided randomly but equally (single-blind control trial study) into two equal groups. Each group contains 20 patients (20 similar fracture sites in each group). Group 1 was treated with open reduction and internal fixation using 2.0 mm non-locking miniplates. Group 2 was treated using locking 2 mm miniplates. **Results:** Of 20 patients treated by conventional 2 mm miniplates, no any patients developed occlusal discrepancy, but one had post-operative mobility at fracture site, and one developed plate failure and subsequent infection, which was treated by removal of the plate under antibiotic coverage. One patient treated by three-dimensional plates had tooth damage. **Conclusion:** Based on the results of this original research concluded that the treatment of various mandibular fractures (parasymphysis, symphysis, and angle) with 2.0 mm locking plates provided three-dimensional stability, more stable configuration with lower meant element stresses and thus showed zero morbidity and was not associated with any major complications. The only probable limitations of locking plates were excessive implant material due to the extra vertical bars incorporated for countering the torque forces.

Key words: Conventional, locking miniplates, mandibular fracture, non-locking miniplates

INTRODUCTION

Monocortical miniplate fixation is a globally accepted and most trusted method for open reduction internal fixation in mandibular fractures. Although placement of a second miniplate may theoretically provide more stability, the clinical importance fixation of the second miniplate a per Champy and Pape^[1] line of osteosynthesis still remains controversial.

The mandibular fractures are one of the most commonly fractured shown in the department or clinics of oral and maxillofacial surgery.^[1] The frequent involvement of the mandibular fractures can be attributed to changes in the lines of calcification and strength from the horizontal body to the vertical line (from symphysis, parasymphysis angle, and ramus mandible), the thinner cross-sectional area, and due to the presence of impacted or partially erupted third molars.^[2] Fractures of the mandibular angle are the most problematic in the facial region because of the high frequency of complications and difficult access to the surgical site.^[3]

Traditional methods of mandibular fractures are reduction and fixation included wire osteosynthesis and maxillomandibular fixation. These fractures are currently treated by plate/screw osteosynthesis and depending on the case, the bone segments are secured by one miniplate fixation, two miniplate fixation,

Access this article online

Publisher



Website:

www.renupublishers.com

DOI:10.30954/2350-0921.01.2018.3

Address for Correspondence:

Dr. Anand Kumar, Department of Dental Surgery, Moti Lal Nehru Medical College, Allahabad, Uttar Pradesh, India.
E-mail: anandkmr901@gmail.com

Submission: 21-09-2017; **Revision:** 16-10-2017; **Acceptance:** 05-12-2017

or by a single rigid plate.^[4,5] However, the discussion about the ideal type of fixation for mandibular angle fractures is still going on. Fixation of mandibular angle fractures is biomechanically complex because the major stress bearing area of the mandible are disrupted in this region.^[6,7] Finite element analysis (FEA) is a numerical analysis technique that can determine the displacements, stresses, and strains, over an irregular solid body given the complex material behavior and the loading conditions imposed on that body. The stress analysis obtained from FEA modeling of the maxillofacial bony structures can provide information regarding interactions between hardware and bone during normal patient functioning.

MATERIALS AND METHODS

This original research was a prospective study carried out on both equally divided groups of undisplaced as well as displaced mandibular fractures, i.e., Group I and II were operated for open reduction and rigid internal fixation (ORIF). This research was done to compare the efficacy between locking and non-locking titanium miniplates in both groups of mandibular fractures for frequency of wound dehiscence, post-operative pain and swelling, development of infection, malocclusion, malunion, screw breakage, and any other technical difficult. Exclusion criteria for this research were infected, malunited, and comminuted fractures as well as mandibular coronoid and condylar fractures. All patients were within the age group of 18–60 years, excluding medically compromised patients. Strict asepsis was followed during whole procedure. Patients were operated either under general anesthesia or local anesthesia. Detailed history, examination chart, and informed consent were taken by each patient before surgery.

All selected patients underwent Erich's arch bar (maxillomandibular fixation) placement preoperatively. Orthopantomogram and posterior-anterior (PA) view of mandible were the standard radiographs for clinical findings before involve in this research. The radiological findings were recorded as fracture site, presence of additional mandibular fracture, and degree of fracture dislocation.

Patients were distributed into two groups and were treated with two of the standard techniques, i.e., one is non-locking miniplate osteosynthesis and other is locking miniplate osteosynthesis. 20 patients were included in each group,

Group I (20 patients): Internal fixation was done with non-locking plate

Group II (20 patients): Internal fixation was done with locking miniplate.

Open reduction and internal fixation of mandibular fracture segments were done intraorally under GA or LA, except in some inaccessible angle fractures where transbuccal

approach was used. In Group I patients, internal fixation of mandibular fracture was done by non-locking plates and in Group II patients locking plate. The surgery was carried out by the same surgical team and the operation technique was the same for most patients.

Depending on the site of fracture, incision was planned and given, and flap was reflected. The fracture site was exposed and fracture ends were manipulated for anatomic reduction. Following reduction of the fragments, temporary maxillomandibular fixation was placed with wires. A suitable plate was selected and bent with a plate bending pliers to confirm the proper adaptation of plates to bone surface on subapical position of teeth, and injury to dental roots was avoided using monocortical screws locking and non-locking plates were placed in equally divided groups according to Champy's line of osteosynthesis.

Follow-up and Evaluation were done Radiographically as well as Clinically

Radiographically by panoramic X-rays view (orthopantomogram), patients' follow-up and evaluation were done on every 1 month, 3 months, and 6 months for any malunion, nonunion, and resorption around screws.

Patients were also advised to visit the department on regular interval for clinical follow-up at an interval of 1 week, 3 weeks, 6 weeks, and also if any problems occur after internal fixation.

RESULTS

In 40 patients, 28 (70%) were male and 12 (30%) were female [Figure 1]. Traffic accident was the etiological factor in 28 (70.00%) patients followed by falls were 4 (10.00%) whereas assault caused fracture were 4 (10.00%) [Figure 2]. Overall, there were seven patients with fractures of the left angle and 10 patients with a fracture on the right side [Figure 2]. 14 (82%) cases had a displaced fracture and 3 (18%) cases were undisplaced with the presence of the impacted wisdom tooth in the fracture line, hence, requiring surgery [Figure 3]. Undisplaced fractures of the angle with no occlusal derangement were treated by simple closed reduction and, hence, not included in the study. After fixation of the miniplate, all fractures appeared to be well reduced and stable. Post-operative occlusion was normal in all, but one patient who showed minor occlusal discrepancies corrected by the use of elastics for 1 week. The PA mandible view was used to assess the patient preoperatively as it best showed the displacement of the fracture. The same view was done postoperatively to assess the reduction and fixation of the fracture. When we analyzed the palpability of the plate after 6 months, it was observed that in 16 (94.12%) cases the plate was palpable only on exerting pressure and 1 (5.88%) case was found to have pain on palpation, with no infection present [Figure

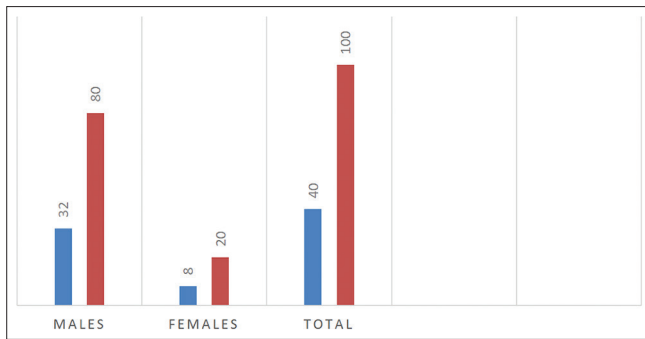


Figure 1: Patients gender distribution

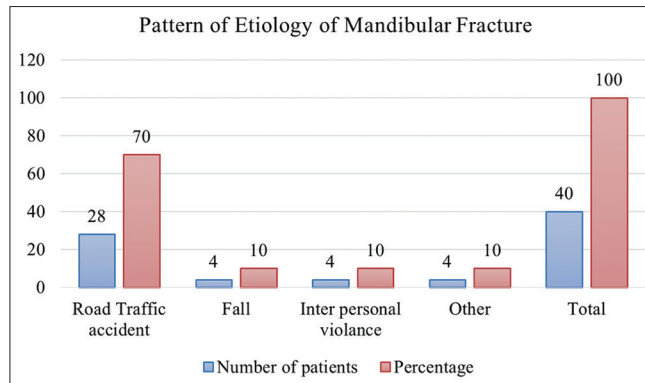


Figure 2: Etiology of mandibular fracture

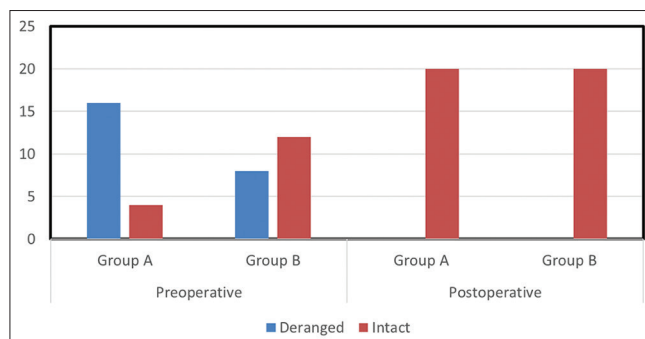


Figure 3: Status of occlusion in both the groups

4]. There was no case of plate exposure, but we encountered three patients with local inflammation due to improper oral hygiene. This was resolved with antibiotics and local oral hygiene methods without any further surgical intervention. There was no case with post-operative paresthesia.

Patients of both groups were evaluated for pain, swelling, hardware failure, malunion, non-union, damage to root by screw, infection at site, neurosensory deficit, occlusal discrepancy, and post-operative mobility at fracture site [Figure 5].

DISCUSSION

In this study, interpersonal violence accounted for 10.00% of the cases, fall injury accounts for 10.00% of cases of mandible

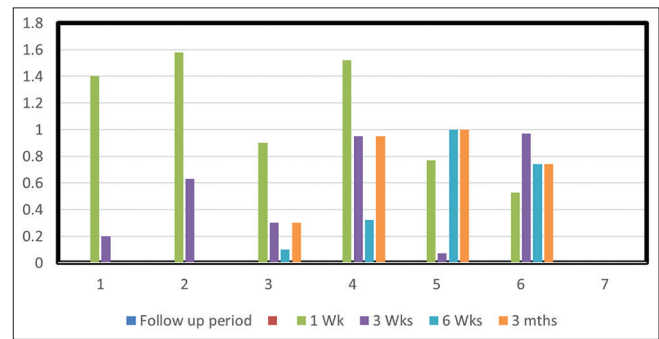


Figure 4: Comparison of pain in both groups

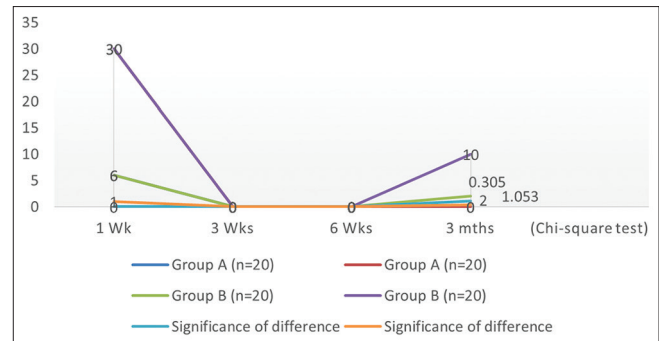


Figure 5: Comparison of swelling in both groups

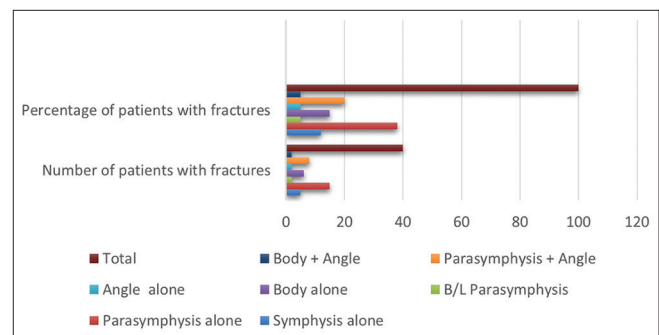


Figure 6: Anatomic distribution of mandibular fracture

fracture. Road trauma was responsible for majority of patients [Figure 2] 70% of mandibular fractures. This is in accordance with the study by Atik *et al.*^[7] [Figure 2]. Of 40 patients in our study 32 (80.00%) were male and 08 (20.00%) were female. This male dominance was also reported by Haug *et al.*^[8] The age group most commonly affected was 21–30 years (40%). Eight patients had bilateral mandible fracture and 12 had unilateral fracture. The most common site of mandible fracture was parasymphysis (35%) and angle (35%), followed by body (20%) and symphysis (10%)

According to Arbeitsgemeinschaft für Osteosynthesefragen (AO)/Association for the Study of Internal Fixation (ASIF) principles,^[9-11] the main aim of ORIF in the reduction of mandibular fractures is to achieve normal occlusion, masticatory functions, undisturbed healing, and immediate restoration of form and function without the adjunctive^[12]

use of maxillomandibular fixation. This approach has become increasingly popular during the past 20 years for all types of mandibular fractures, and diverse plating systems have been developed to meet this fundamental requirement.^[13-16] The locking plating system has been developed and popularized by AO/ASIF to obviate the main disadvantage of conventional plate system, which requires the plate to be perfectly adapted to the underlying bone to avoid gaping of the fracture and associated instability. This bone plate system acts as an internal-external fixator, which results in better distribution of the load and prevents load concentration on a single screw, thus decreasing the risk of a screw's loosening and stripping. Moreover, because anatomic adaptation of the plate to the underlying bone contour is not crucial, there are theoretically fewer interferences with the adjacent vascular supply.^[17,18]

Our study reviews the efficacy of 2.0 mm locking plate/screw system in 20 patients requiring open reduction and internal fixation without maxillomandibular fixation. The patients were evaluated for the location, type, and number of fractures; the presence of tooth in line, time elapsed between the presentations of the patient after trauma, pre- and post-surgical occlusal relationship, adequacy of reduction on post-operative radiograph, and any post-surgical complications requiring a secondary surgical intervention.

In this study, 32 fractures were observed in the 20 patients selected. Open reduction and internal fixation were carried out in standard operating protocol using either an intraoral or an extraoral approach. The system was found to be reliable and effective treatment modality of mandibular fractures. Our observations do correlate with those of the study conducted by Ayman *et al.* (2005) [Figure 6].^[19-21]

Post-operative complications were noted in two patients. One developed an intraoral wound dehiscence which was treated with antibiotics and local measures. There was one major complication (3.125%) with infection at fracture site requiring incision and drainage and subsequent miniplate removal after 5 weeks of fracture treatment. Primary bone healing was noted in 93.75% of fracture sites with an overall post-operative complication of 6.25% in the study. Our study observations do correlate with those of the study conducted by Edward Ellis III and John Graham (2002).

CONCLUSION

The most common cause of mandibular fracture was found to be road traffic accidents, and males were most commonly affected in both genders. Patients between 16 and 30 years of age were mostly affected by mandibular fracture in which parasymphysis followed by parasymphysis with angle and parasymphysis bilateral with angle fracture was seen. Of 40 patients, few patients were found infected postoperatively

in follow-up and swelling was gradually subsided in next followup week.

We concluded that the locking miniplates have advantage over non-locking plates in mandibular fractures and were found to more efficacious enough to bear masticatory loads as it offers good resistance during the osteosynthesis of fracture. It gives the advantage of greater stability, increased bite force, less precision required in plate adaptation because of the "internal/external fixator," and less alteration in periosteal blood supply. However, almost similar results were seen in standard miniplate osteosynthesis.

REFERENCES

1. Champy M, Pape HD. The strasbourg miniplate osteosynthesis. In: Kruger E, Schilli W, editors. Oral and Maxillofacial Traumatology. Vol. 2. Berlin: Quintessence; 1986. p. 19-43.
2. Esen A, Dolanmaz D, Tüz HH. Biomechanical evaluation of malleable noncompression miniplates in mandibular angle fractures: An experimental study. *Br J Oral Maxillofac Surg* 2012;50:e65-8.
3. Suer BT, Kocyigit ID, Kaman S, Tuz HH, Tekin U, Atil F. Biomechanical evaluation of a new design titanium miniplate for the treatment of mandibular angle fractures. *Int J Oral Maxillofac Surg* 2014;43:841.
4. Kimsal J, Baack B, Candelaria L, Khraishi T, Lovald S. Biomechanical analysis of mandibular angle fractures. *J Oral Maxillofac Surg* 2011;69:3010-4.
5. Ribeiro PD Jr, Magro-Filho O, Shastri KA, Papageorge MB. *In vitro* evaluation of conventional and locking miniplate/screw systems for the treatment of mandibular angle fractures. *Int J Oral Maxillofac Surg* 2010;39:1109-14.
6. Chrcanovic BR. Fixation of mandibular angle fractures: *In vitro* biomechanical assessments and computer-based studies. *Oral Maxillofac Surg* 2013;17:251-68.
7. Atik F, Ataç MS, Özkan A, Kilinç Y, Arslan M. Biomechanical analysis of titanium fixation plates and screws in mandibular angle fractures. *Niger J Clin Pract* 2016;19:386-90.
8. Haug RH, Street CC, Goltz M. Does plate adaptation affect stability? A biomechanical comparison of locking and nonlocking plates. *J Oral Maxillofac Surg* 2002;60:1319-1326.
9. Agarwal M, Mohammad S, Singh RK, Singh V. Prospective randomized clinical trial comparing bite force in 2-mm locking plates versus 2-mm standard plates in treatment of mandibular fractures. *J Oral Maxillofac Surg* 2011;69:1995-2000.
10. Chiodo TA, Ziccardi VB, Janal M, Sabitini C. Failure strength of 2.0 locking versus 2.0 conventional syntheses mandibular plates: A laboratory model. *J Oral Maxillofac Surg* 2006;64:1475-9.
11. Collins CP, Pirinjian-Leonard G, Tolas A, Alcalde R. A prospective randomized clinical trial comparing 2.0-mm locking plates to 2.0-mm standard plates in treatment of mandible fractures. *J Oral Maxillofac Surg* 2004;62:1392-5.
12. Singh V, Kumar I, Bhagol A. Comparative evaluation of 2.0-mm locking plate system vs. 2.0-mm nonlocking plate system for mandibular fracture: A prospective randomized study. *Int J Oral Maxillofac Surg* 2011;40:372-7.
13. Jain MK. Comparison of 3-dimensional and standard miniplate fixation in the management of mandibular fractures. *J Oral Maxillofac Surg* 2010;68:156-72.
14. Abotaleb BM, Al Moraissi E, Zhiqiang W, Ping C, Yongjie K, Alkebsi K, *et al.* A detailed analysis of mandibular fractures epidemiology, treatment and outcomes: A 5-year retrospective study, Gansu Province-China. *J Oral Maxillofac Surg Med Pathol* 2018;30:197-205.

15. Sehgal S, Ramanujam L, Prasad K, Krishnappa R. Three-dimensional v/s standard titanium miniplate fixation in the management of mandibular fractures—a randomized clinical study. *J Craniomaxillofac Surg* 2014;42:1292-9.
16. Malhotra K, Sharma A, Giraddi G, Shahi AK. Versatility of titanium 3D plate in comparison with conventional titanium miniplate fixation for the management of mandibular fracture. *J Maxillofac Oral Surg* 2012;11:284-90.
17. Khalifa ME, El-Hawary HE, Hussein MM. Titanium three dimensional miniplate versus conventional titanium miniplate in fixation of anterior mandibular fractures. *Life Sci J* 2012;9:1006-10.
18. Sawatari Y, Marwan H, Alotaibi F, Christensen J, Gannon J, Peleg M. The use of three-dimensional strut plates for the management of mandibular angle fractures: A retrospective analysis of 222 patients. *Int J Oral Maxillofac Surg* 2016;45:1410-7.
19. Chritah A, Lazow SK, Berger JR. Transoral 2.0-mm locking miniplate fixation of mandibular fractures plus 1 week of maxillomandibular fixation: A prospective study. *J Oral Maxillofac Surg* 2005;63:1737-41.
20. Balakrishnan R, Ebenezer V, Dakir A. Three dimensional titanium mini plates in management of mandibular fractures. *Biomed Pharmacol J* 2014;7:241-6.
21. Cillo JE Jr., Ellis E IIIrd. Treatment of patients with double unilateral fractures of the mandible. *J Oral Maxillofac Surg* 2007;65:1461-9.

How to cite this article: Yadav M, Yadav N, Kumar A. Comparison of Conventional 2.0 mm Non-Locking and Locking Miniplates in Management of Fracture Mandible. *Int J Dent Med Spec* 2018;5(1):13-17.

Source of Support: None; **Conflict of Interest:** None